

# A NOVEL SURFACE 3-D IMAGING SYSTEM FOR PSORIATIC LESIONS.



ICS-FORTH



UOC

A. Kokolakis<sup>4</sup>, K. Lasithiotakis<sup>2,4</sup>, S. Psycharakis<sup>3,4</sup>, K. Krasagakis<sup>1,4</sup>,  
S. Kruger-Krasagakis<sup>1,4</sup>, X. Zabulis<sup>3</sup>, T. Sarmis<sup>3</sup>, P. Panteleris<sup>3</sup>, G. Georgiadis<sup>4</sup>,  
I. Karatzanis<sup>3</sup>, C. Stephanidis<sup>3</sup>, A. Tosca<sup>1,4</sup>

<sup>1</sup> Department of Dermatology, Faculty of Medicine, University of Crete, 71110 Heraklion, Greece

<sup>2</sup> Department of Surgery, Faculty of Medicine, University of Crete, 71110 Heraklion, Greece

<sup>3</sup> Computational Vision and Robotics Laboratory of the Institute of Informatics, Foundation for Research and Technology Hellas, 71110 Heraklion, Greece

<sup>4</sup> Faculty of Medicine, University of Crete, 71110 Heraklion, Greece

## Introduction

Psoriasis is a chronic, non-contagious disease that affects mainly the skin. It is currently suspected to be autoimmune in origin. It commonly causes red, scaly patches to appear on the skin, although some patients have no dermatological symptoms. The scaly patches caused by psoriasis, called psoriatic plaques, are areas of inflammation and excessive skin production. Skin rapidly accumulates at these sites and takes on a silvery-white appearance. Plaques frequently occur on the skin of the elbows and knees, but can affect any area including the scalp, palms of hands and soles of feet, and genitals. In contrast to eczema, psoriasis is more likely to be found on the extensor aspect of the joint.

The disorder is a chronic recurring condition that varies in severity from minor localized patches to complete body coverage. Fingernails and toenails are frequently affected (psoriatic nail dystrophy) and can be seen as an isolated finding. Psoriasis can also cause inflammation of the joints, which is known as psoriatic arthritis. Ten to fifteen percent of people with psoriasis have psoriatic arthritis.


The cause of psoriasis is not known, but it is believed to have a genetic component.

Factors that may aggravate psoriasis include stress, withdrawal of systemic corticosteroid, excessive alcohol consumption, and smoking. There are many treatments available, but because of its chronic recurrent nature psoriasis is a challenge to treat.

Our aim was to develop a novel imaging technique for the evaluation of the treatment in psoriatic patients.

## Stereoscopic Imaging Device

The device, which was developed, consists of a combination of 3 high resolution digital cameras and a sophisticated LED based illumination system which improves the focus of the lesion. The 3 high resolution cameras are placed in linear arrangement with the capability of adding more cameras. The acquired images are stereoscopically processed to obtain a metric and photorealistic 3-D reconstruction of the lesion. The sophisticated LED based illumination system improves the focus of the lesion and consequently contributes to a higher level of accuracy in the surface 3-D reconstruction of the psoriatic lesions. Accompanying custom-developed software enables the visualization and inspection of the photorealistic 3-D reconstruction as well as the performance of metric measurements on its surface and volume. Its purpose is to facilitate the analysis and comparison of sequential images of psoriatic lesions from different patients.



## Patients - Methods

In this interdisciplinary study, we recruited an homogenized sample of patients, according to five different parameters. We investigated 62 patients, suffering from psoriasis at least once a year for a 2-y period from August 2009 to July 2011. Detailed data from the patients in our series is analyzed below. Data was extracted regarding patient demographics, patient symptoms, primary site of the lesion, size and location of the lesion, treatment and patient response to various treatments. Out of 62 patients with reported gender information, 33 were men and 29 were women. As far as men are concerned, we encountered the problem of dense hairing around the lesions which obstructed the detailed 3-D reconstruction.

In order to quantify the patients symptoms, we used the scale of PASI score. Patients in this study were included only if their PASI score was over 5.5. Over this PASI score, the lesions' width was adequate, in order to be captured. Furthermore, the primary site of the lesion was critical for the selection of the patients. All the captured lesions, that were analyzed were on flat surfaces of the body. This factor is crucial for our study, because the morphology of the skin could have a detrimental effect on the quality of the pictures.

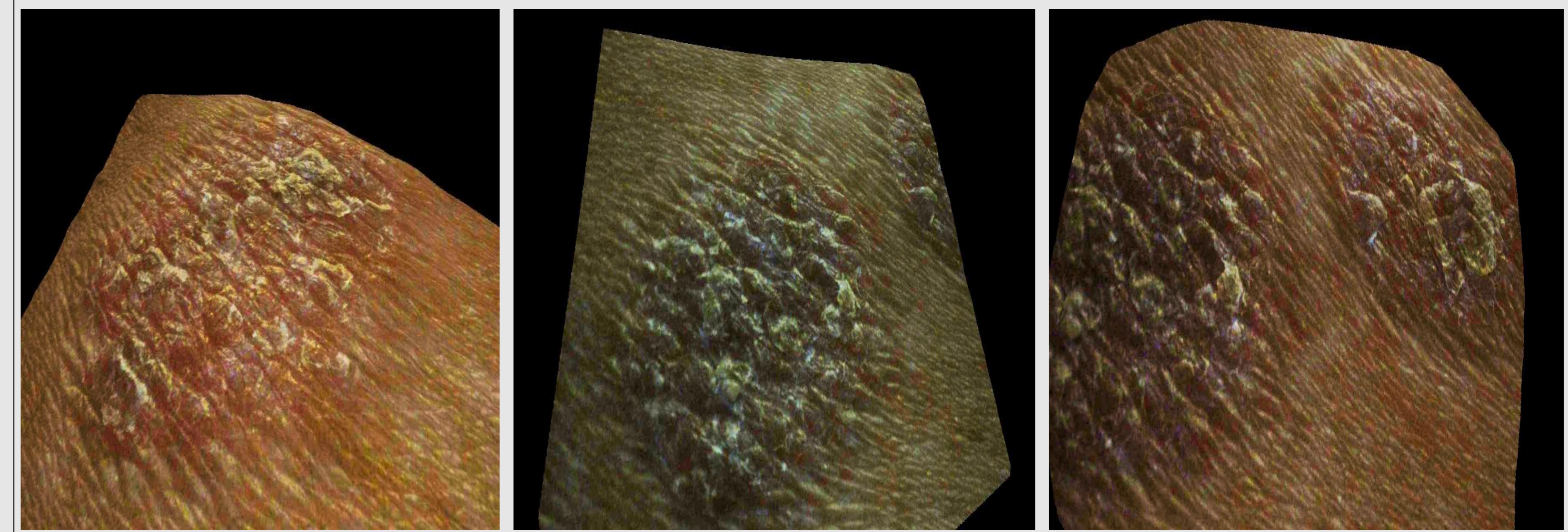
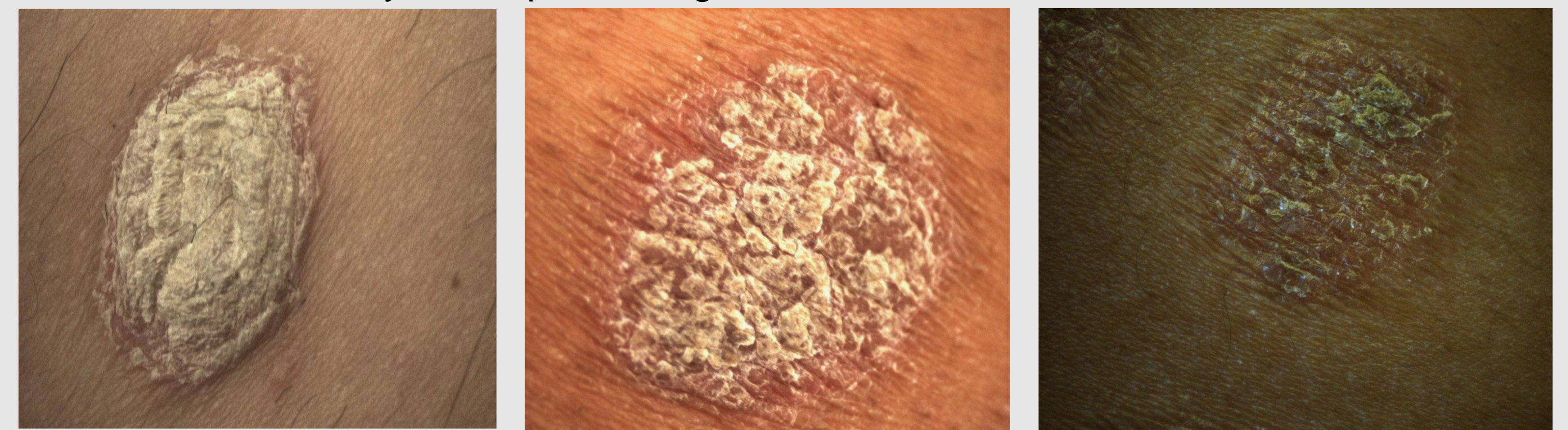In addition, the size of the lesion was a significant factor for our study. The area of the lesion was measured in cm<sup>2</sup> and was no more than 5 cm<sup>2</sup>, according to the layout and the settings of our device. Finally, for our project's purposes we studied patients undergoing a variety of treatments and we analyzed their response to each therapy applied.

Imaging of the lesions of psoriatic patients was performed in-vivo with the use of an original stereoscopic imaging device, designed and developed by the Computational Vision and Robotics Laboratory of the Institute of Informatics of the Foundation for Research and Technology-Hellas, in cooperation with the Department of Dermatology, according to the analysis of requirement elaborated by the Department of Dermatology. Comparisons of the obtained surface 3-dimensional reconstructions were performed in cooperation with the Biomedical Informatics Laboratory of the Foundation for Research and Technology Hellas. Finally, differences of the obtained sequential 3-D reconstructions were compared with clinical and histological measures of response to anti-psoriatic treatments.

## Results and Discussion

Our results show that surface 3-D imaging might reproducibly and accurately used for the evaluation of response of psoriatic lesions to various treatments. 3-D reconstruction provides a different view into the normal and diseased skin. It contributes to a special vision of the morphology of the lesion and its surrounding tissue, providing higher level of accuracy and more details about the architecture of the psoriasis lesion. This data can be used for a more reliable pre-treatment assessment, leading to a more rapid and effective response to the treatment. In our study, patients' lesions were assessed in the whole duration of the treatment, as the extent of the psoriasis lesion has to be assessed in order to determine if the treatment has the expedient efficacy.

3-D reconstruction can be useful into calculating various characteristics of the psoriasis lesion such as area, thickness, pattern and boundary. This technique grants a lot of details and presents a prominent advantage in comparison to the ordinary 2-dimensional imaging systems because of the 3 high resolution cameras in linear arrangement and the projector, which illuminates the lesion with a textural pattern that is focused on its surface and enhances the accuracy of this processing.



## Conclusions

Our results show that surface 3-D imaging might reproducibly and accurately used for the evaluation of response of psoriatic lesions to various treatments. Furthermore, our novel surface 3-D imaging system presents a prominent advantage in comparison to the ordinary 2-dimensional imaging systems and contributes decisively to a non invasive, rapid and precise evaluation of the treatment applied, compared with conventional clinical and histological measures. The surface 3-D imaging is not only useful for the evaluation of the architecture and various information of psoriasis lesions and the response to the treatment applied, but also it might proved to be substantial in extracting new data for the pathology, treatment and prognosis of psoriasis, representing a useful tool for the dermatologists. Surface 3-D imaging, is a promising, accurate, rapid and easy to handle technique that might aid in the documentation and the surveillance of psoriatic lesions under treatment.

## References

- (1) M. H. Ahmad Fadzil, Dani Ihtatho, M. A. Azura, H. H. Suraiya, "Objective Assessment of Psoriasis Erythema for PASI Scoring", 30th Annual International Conference of the IEEE EMBS 2008, Vancouver, Canada, 2008.
- (2) Hermawan Nugroho, Naz-e-Batool, M. H. Ahmad Fadzil, P. A. Venkatachalam, "Surface Analysis of Psoriasis for PASI Scaliness Assessment", Proceedings International on Intelligent and Advanced Systems (ICIAS2007), Kuala Lumpur, Malaysia.
- (3) Dani Ihtatho, M. H. Ahmad Fadzil, M. A. Azura, H. H. Suraiya, "Automatic PASI Area Scoring", Proceedings International on Intelligent and Advanced Systems (ICIAS2007), Kuala Lumpur, Malaysia.
- (4) Dani Ihtatho, M. H. Ahmad Fadzil, M. A. Azura, H. H. Suraiya, "Area Assessment of Psoriasis Lesion for PASI Scoring", Proceedings of the 29th Annual International Conference of the IEEE EMBS 2007, Lyon, France.
- (5) Three-Dimensional (3D) High-Frequency Ultrasound Images of Skin and an Eye Kumi Kamada1., Osamu Oshiro1, Kunihiko Chihara1, Wojciech Secomski2 and Andrzej Nowicki2
- 1Graduate School of Information Science, Nara Institute of Science and Technology, Takayama 8916-5, Ikoma, Nara 630-0101, Japan
- 2Polish Academy of Science, Warsaw 00-049, Poland
- (6) Three-dimensional surface imaging for clinical trials: improved precision and reproducibility in circumference measurements of thighs and abdomens. Weiss ET, Barzilai O, Brightman L, Chapas A, Hale E, Karen J, Bernstein L, Geronemus RG. Laser & Skin Surgery Center of New York, New York, NY 10016, USA.
- (7) Obtaining malignant melanoma indicators through statistical analysis of 3D skin surface disruptions. Ding Y, Smith L, Smith M, Sun J, Warr R. Machine Vision Laboratory, DuPont Building, University of the West of England, Bristol Frenchay Campus, Bristol BS16 1QY, UK.
- (8) The accuracy of matching three-dimensional photographs with skin surfaces derived from cone-beam computed tomography. Maal T J, Plooi J M, Rangel FA, Mollemans W, Schutyser FA, Bergé S J.
- (9) 3D Facial Imaging Research Group Nijmegen-Bruges, Department of Oral and Maxillofacial Surgery, Radboud University Nijmegen Medical Centre, Nijmegen, The Netherlands.
- ReviewUpdate in three-dimensional imaging in facial plastic surgery. Curr Opin Otolaryngol Head Neck Surg. 2004 Aug; 12(4):327-31.